

THE INFLUENCE OF PROSTHESIS TYPE AND SURGICAL APPROACH IN THE DEVELOPMENT OF HETEROTOPIC OSSIFICATIONS – CLINICAL AND RADIOLOGIC EVALUATION AFTER HIP REPLACEMENT

F.L.P SABOU¹ R. D. NECULA^{1,2} A.M. PASCU²
I. ŞAMOTĂ²

Abstract: *Heterotopic ossifications can be a complication of hip replacement and more and may influence, according to their development, the mobility of the prosthetic hip. However, there are inconsistencies between the degree of development and the degree of articular influence measured by Harris Hip Score. We have tried to correlate the type of prosthesis, the type of approach used in hip replacement and the development of heterotopic ossifications 1-3 years after the surgery.*

Key words: *heterotopic ossification, hip replacement, surgical approach.*

1. Introduction

Initially, any calcium storage in the human body, no matter its location, was named calculus without clearly differentiating between those occurring in tissues as muscles or skin, viscera or in cavities. Starting with the development of the optical microscope, Virchow the founder of modern pathology, describes the differences between normal bone calcification, the forming of calculi in cavities and the pathological ossification of soft tissue [16].

Described and named differently in medical literature: paraosteoarthropathy, ossifying myositis, neoformed periarticular bone, ectopic periarticular ossification, neurogenic osteoma, neurogenic ossifying myopathy or heterotopic calcifications, heterotopic ossification is the most used term, being regarded as the most descriptive and precise [18].

It is defined as the presence or formation of mature lamellar bone tissue within the structure of soft tissues (skin, muscle, ligaments, viscera) where they are not encountered normally. Heterotopic ossifications have as a main criteria for

¹ Orthopaedics Clinic, Brasov County Emergency Clinical Hospital, Brasov, Romania.

² Faculty of Medicine, *Transilvania* University of Braşov, Romania.

diagnosis the presence of bone cells, of collagen matrix and hydroxyapatite crystals. [3], [12].

Biochemical, immunohistochemical and morphological studies concerning heterotopic ossifications from different places and different pathological conditions showed that they are formed by and contain parts similar to the normal skeletal bone [10].

Heterotopic ossifications, seen as a complication of hip surgery especially after hip replacement or fractures, are best described in literature due to their possible consequences if not treated accordingly. Data shows a general occurrences between 5-10% to 90%, depending on the study [5], [6], [11].

After hip replacement, their occurrence varies between 16-53%, depending on factors related to the study, such as: data collecting and analysis, the time and type of population studied [2].

2. Materials and Methods

We have performed an analytical study in which we dealt with a clinical evaluation of the global hip function at patients displaying arthroplasty connected to the radiologic presence of heterotopic ossifications in different degrees, as well as the existence of a correlative between their development and the type of prosthesis used (cemented/uncemented, total/partial), also taking into account the type of surgical approach used for implantation (anterolateral/lateral).

The present prospective cohort study was applied on 76 patients displaying total or partial, unilateral or bilateral hip arthroplasty who underwent surgery between January 2006 and December 2008 at Brasov County Emergency Clinical

Hospital, Orthopaedics - department. Their evolution was further assessed within the period from 1 to 3 years after the operation.

Patients were randomly chosen to take part in the study from our clinic's database and called or invited in writing to join the research.

The diagnosis was made according to their case history, clinical and radiological exams.

The clinical assessment was made from the perspective of the hip functionality displayed by the operated hips correlated to the international assessment standards, meaning the Harris Hip Score.

For the radiological assessment we used a-p hip or pelvis X-rays where we tried to highlight the presence of heterotopic ossifications as a complication of hip replacement surgery.

In cases of positive presence of heterotopic ossifications were classified according to the Brooker Classification.

Developed in the 1973, Brooker Classification represents a standard nowadays due to its simplicity and fast diagnosis (it only needs a simple a-p X-ray of the pelvis or hip) and it is the most frequently used method of diagnosis and quantify for the evolution of heterotopic ossifications after hip replacement.

Classification of heterotopic ossifications after Brooker: [4]

- 1st degree – Islands of bone within soft tissues around the hip joint.
- 2nd degree - Bone spurs at the level of the pelvis or proximal femur, leaving at least 1 cm away between the opposite bone surfaces.
- 3rd degree - Bone spurs at the level of the pelvis and/or the proximal femur within 1 cm between opposite surfaces.
- 4th degree - Radiological bony ankylosis of the hip.

For statistical processing of the data's collected we used Epi-Info software, version 3.4.3. – November 2007. The confidence interval was determined with the CI set at 95%.

In the final part of the study, patients displaying heterotopic ossifications from both cohorts were added together, and the resulting data's were statistically processed according to contingency table 2×2, calculating the relative risk (RR) and the statistical significance of the epidemiologic consequence was checked (in this case, involving qualitative dichotomous variables where we applied a statistical test chi squared type).

In order to check research hypothesis and scientific conclusions stating the significant difference between the two groups of patients (exposed/unexposed), χ^2 method was used. The result was compared for a risk of 5% (95% probability) to numbers in chi-squared table.

χ^2 was calculated, and in the case of being greater than 3,84, we considered the H_0 hypothesis rejected with a lower risk of 5%.

3. Results

Within the 76 patients invited to take part in the present study, 43 managed to come (57%). The reasons involved were: the inability to leave home (9 patients), decease (5 patients) and other reasons (19 patients).

In the case of the first category, the cause was probably the secondary outcome of arthroplasty closely connected with old age, for the second the causes derived from other health problems, while the third resided from not agreeing to take part in the study.

Within the 43 assessed, 11 patients

presented with bilateral hip arthroplasty, as a consequence the total number of prosthetic hips that were studied was 54.

The largest age group of patients with arthroplasty was that belonging to 60-70, a possible consequence of coxarthrosis at this stage in life. The average age of the studied group was of 72.97, within a low point of 48 and a maximum point of 83. From the gender's point of view we noticed a majority represented by female patients with an average of 74.3 years of age, while the male patient's average age was 70.1.

From the point of view of the etiologic diagnosis, the largest category of hips undertook surgery for primary coxarthrosis – 35 cases (65%), while other reasons were secondary coxarthrosis – 6 cases (11%), femoral neck fracture – 12 cases (22%) and hip socket inflammation after unipolar hip replacement- 1 case (2%).

There were 44 hips (81%) that underwent the modified lateral approach (modified Hardinge) and 10 hips (19%) with an anterolateral approach (Watson-Jones).

Totally cemented prostheses was used in the majority of cases (57%), while the uncemented prosthetic and partial Austin Moore were used in 24% and 19% of the patients.

The global Harris Hip Score may be considered to be satisfactory, taking into account that approximately 60% of the total number of hips displayed good and very good clinical results.

The radiologic results regarding the presence of heterotopic ossifications may also be considered satisfactory, 59% of the hips not having this complication developed.

Within the 22 studied hips (41%) which displayed heterotopic ossifications, 11 (20.4%) were of the 1st degree, 7 (13%) –

2nd degree, 4 (7,4%) – 3rd degree, while none of them displayed apparent ankylosis, respectively 4th degree.

In comparing clinical results (hip functionality according to Harris Hip Score) to the radiological ones (the degree of development for heterotopic ossification according to Brooker), the studied group displayed a lack of epidemiologic link with no statistical significance between the hip's function and the degree of heterotopic ossification (RR=0.52, even

protection factor ($0.14 < RR < 1.94$), $\chi^2=1.13$). As seen in the table below (Table 1), hips with no heterotopic ossification can range in point of clinical score from very good to unsatisfactory, while 3rd degree heterotopic ossification all have a very good clinical score, thus suggesting that heterotopic ossification may not display any symptoms and have a very low influence on the quality of life in advanced grades.

Table 1

Total Harris Hip Score depending on heterotopic ossifications degree

HETEROTOPIC OSSIFICATIONS GRADE					
TOTAL HARRIS HIP SCORE	GRADE 0	GRADE 1	GRADE 2	GRADE 3	PATIENTS NUMBER
EXCELENT	8	5	4	4	21
VERY GOOD	5	2	1	0	8
GOOD	7	1	0	0	8
FAIR	5	1	1	0	7
POOR	7	2	1	0	10
TOTAL	32	11	7	4	54

As proof to the conclusion stated before, I am going to exemplify the incongruence between the heterotopic ossification degree of development according to Brooker and the Harris Hip Score based on 4 cases:

Case 1. Female patient, 53 y.o, uncemented THR of the right hip, with the etiological diagnosis of primary coxarthrosis. The approach used was lateral. Harris Hip Score is very good (94 points). We notice the absence of heterotopic ossification. (Fig. 1)

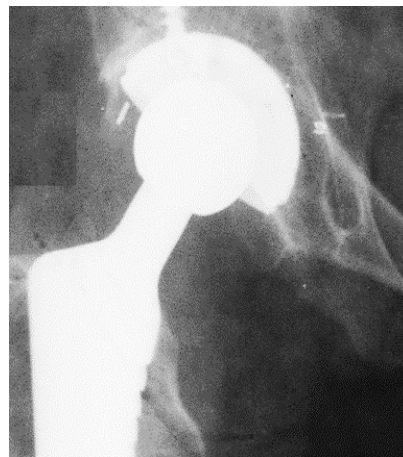

Fig. 1. *Right hip X-ray showing the absence of heterotopic ossification.*

Case 2. Female patient of 72 y.o displaying a cemented THR of the left hip, with the etiological diagnosis of primary

coxarthrosis. The approach used was lateral. Harris Hip Score is good (80 points). We notice a 1st degree heterotopic ossification. (Fig. 2)

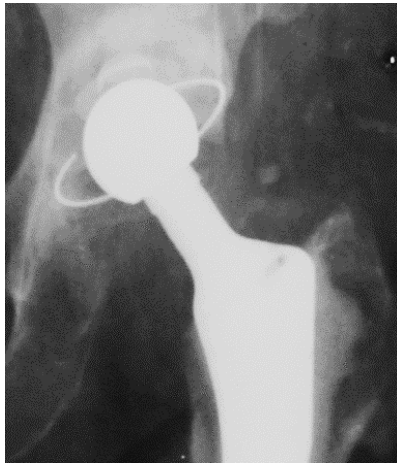


Fig. 2. *Left hip X-ray showing 1st degree heterotopic ossification.*

Case 3. Cemented THR of the left hip at a female patient of 63, with an etiological diagnosis of coxarthrosis secondary to congenital hip dislocation operated on at the age of 2. The approach used was Watson-Jones. Harris clinical score is good (80 points). We notice a 2nd degree heterotopic ossification. (Fig. 3)

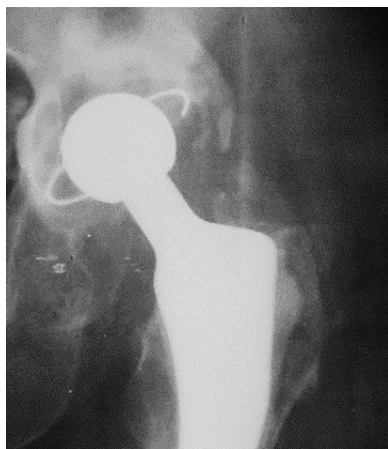

Fig. 3. *Left hip X-ray showing 2nd degree heterotopic ossification.*

Case 4. Cemented THR of the left hip at a male patient of 60, with an etiological diagnosis of secondary coxarthrosis to avascular necrosis of the femoral head. Clinical score is very good (98 points). The approach used was Watson Jones. We notice a 3rd degree heterotopic ossification and a lack of correlation between Harris score and the high degree of heterotopic ossification. (Fig. 4)

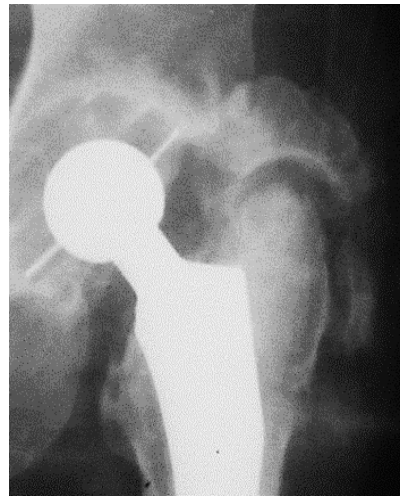

Fig. 4. *Left hip X-ray showing 3rd degree heterotopic ossification.*

We started from the hypothesis that type of prosthesis used may be related to the development of heterotopic ossification.

The present study shows no epidemiologic connection between the type of prosthesis and the development of heterotopic ossification, data resulted from the use of totally cemented prostheses ($RR=1.59$; $0.78 < RR < 3.26$; $\chi^2=1,76$) and uncemented prostheses ($RR=1,18$; $(0,59 < RR < 2,38)$ $\chi^2=0,21$) being insignificant.

The surgical approach may also be involved in the occurrence of heterotopic ossifications after surgery. The percentage of heterotopic ossifications in the case of

hips with lateral approach from the studied group was of 36% (decreasing from 1st to 3rd degree), while those with Watson-Jones – 60% (constant from 1st to 3rd degree).

In comparing radiological results (degrees of heterotopic ossification) to types of approach, the study showed that hips with Watson-Jones approach are risk factors involved in developing heterotopic ossifications, displaying a risk growth by 2.2 units to that of lateral approach, statistically significant data. $RR=2,2$ ($1,41 < RR < 3,44$), $\chi^2=10,47$

4. Discussions

Various studies have been conducted over the years trying to highlight the importance of the surgical approach and the implanted prosthesis type in relation to the occurrence of heterotopic ossifications.

The approach type used in hip replacement surgery can influence wide the heterotopic ossifications occurrence noticing a higher rate in case of transtrochanteric approach with higher grade of heterotopic ossifications development compared with the lateral approach with lower grades of development but higher frequency [19].

The classic Hardinge lateral approach predispose more frequent to heterotopic ossifications compared with the modified lateral one [7], [8]

In case of Liverpool approach heterotopic ossifications development occurred in higher grades and five time more frequent compared with lateral Hardinge and transtrochanteric approach [15].

The use of posterior approach predispose least to heterotopic ossifications compared

with anterolateral and transtrochanteric approach [13]. The anterolateral approach increase the rise for periprosthetic heterotopic ossifications in comparison with the posterior approach [1].

In case of prosthesis type have been reported differences between cementedless and hybrid prosthesis type (cemented femoral component and uncemented acetabular cup) with a higher rate of heterotopic ossifications occurrence and excision interventions in case of cementedless femoral component [9].

Opinions are divided regarding total cementedless and uncemented prosthesis types, some authors found no differences in heterotopic ossifications occurrence between them, affirming that the prosthesis type should not be an impediment in prosthesis type selection [14], [17].

5. Conclusions

The occurrence of different degrees of heterotopic ossifications in the studied group was of 41% from which 20.4% - 1st degree, 13% - 2nd degree, 7.4% - 3rd degree and 0% - 4th degree.

There is no statistically significant epidemiological connection between hip functionality assessed according to Harris score and the degree of heterotopic ossification.

Total cemented and uncemented prostheses types are not related epidemiologically to the occurrence of heterotopic ossification, unlike partial prostheses which are statistically proven to act as a protective factor.

The anterolateral approach increases the chance of developing heterotopic ossifications by 2.2 in comparison to the modified lateral one.

References

1. Bischoff, R., Dunlap, J., Carpenter, L., DeMouy, E., Barrack, R.: *Heterotopic ossification following uncemented total hip arthroplasty: effect of the operative approach*. In: The Journal of arthroplasty. 1994; 9:641-644.
2. Bossche, L.V., Vanderstraeten, G.: *Heterotopic ossification: a review*. In: J. Rehabil Med. 2005; 37(3):129-36.
3. Bosse, A.: *Klinik, Differential-diagnose und Histogenese der heterotopen Ossifikation*. In: Veroff Pathol 1997; 146:1 168
4. Brooker, A.F., Bowerman, J.W., Robinson R.A., Riley L.H. Jr.: *Ectopic ossification following total hip replacement: incidence and a method of classification*. In: J BoneJoint Surg [Am] 1973; SS-A:1629-32.
5. Dalury, D.F., Jiranek, W.A.: *The incidence of heterotopic ossification after total knee arthroplasty*. In: The Journal of Arthroplasty 2004 June; 19(4):447-452.
6. Fijn, R., Koorevaar, R.T., Brouwers, J. R.: *Prevention of heterotopic ossification after total hip replacement with NSAIDs*. In: Pharmacy World and Science 2003; 25(4):138-145.
7. Foster, D.E., Hunter, J.R.: *The direct lateral approach to the hip for arthroplasty. Advantages and complications*. In: Orthopedics 1987, Feb; 10:274-280.
8. Frndak, P.A., Mallory, T.H.: *Translateral Surgical Approach to the Hip: The Abductor Muscle Split*. In: Clinical orthopaedics and related research 1993; 295:135-141.
9. Maloney, W.J., Krushell, R.J., Jasty, M., Harris, W.H.: *Incidence of heterotopic ossification after total hip replacement: effect of the type of fixation of the femoral component*. In: J Bone Joint Surg Am. 1991 February; 73(2):191-3.
10. Jowsey, J., Coventry, M.B., Robins, P.R.: *Heterotopic ossification: theoretical consideration, possible etiologic factors, and a clinical review of hip arthroplasty patients exhibiting this phenomenon*. In: The Hip. Proceedings of the Fifth Open Scientific Meeting of the Hip Society. St Louis: CV Mosby, 1977:210-21.
11. Koulouvaris, P., Sherr, D., Sculco, T.: *Incidence of Heterotopic Ossification in Patients Receiving Radiation Therapy following Total Hip Arthroplasty*. In: Advances in Orthopedic Surgery 2014 April; 1-4.
12. McKee, G.K.: *Artificial hip joint*. In: J. Bone Joint Surg. Br 1951; 33:465.
13. Morrey, B.F., Adams, R.A., Cabanela, M.E.: *Comparison of heterotopic bone after anterolateral, transtrochanteric, and posterior approaches for total hip arthroplasty*. In: Clinical orthopaedics and related research 1984; 188: 160-167.
14. Nayak, K.N., Mulliken, B., Rorabeck, C.H., Bourne, R.B., Woolfrey, M.R.: *Prevalence of heterotopic ossification in cemented versus noncemented total hip joint replacement in patients with osteoarthritis: a randomized clinical trial*. In: Can J Surg. 1997 October; 40(5):368-74.
15. Pai, V.: *Heterotopic ossification in total hip arthroplasty: the influence of the approach*. In: The Journal of arthroplasty 1994; 9:199-202.
16. Panait, Gh., Panait, A., Budica, C., Necula, R.: *Mineralizarea biologică și modelarea adaptativă biomecanică a oaselor. Osteoporoza (Biological mineralization and biomechanics adaptive modeling of bones*.

- Osteoporosis*). Bucureşti. Editura Publistar, 2009. ISBN 973-873311-9-7
17. Purtil, J.J., Eng, K., Rothman, R.H., Hozack, W.J.: *Heterotopic ossification: incidence in cemented versus cementless total hip arthroplasty*. In: *The Journal of arthroplasty* 1996; 11: 58-63.
18. Sawyer, J.R., Myers, M.A., Rosier, R.N., et al.: *Heterotopic ossification: Clinical and cellular aspects*. In: *Calcif Tissue Int* 1991; 49:208 –215.
19. Testa, N., Mazur, K.: *Heterotopic ossification after direct lateral approach and transtrochanteric approach to the hip*. In: *Orthopaedic review* 1988; 17:965-971.